



**PATIENT**

Bobby Alves

**PRESENTING CLINICAL SIGNS**

History: Grade II-III/VI systolic murmur. Coughing.

**SPECIES**

Canine

**ECHOCARDIOGRAM FINDINGS**

2D, m-mode, color flow and Doppler imaging is available.

**Left ventricle:** The LV diameter is normal with adequate myocardial function. LV wall thicknesses are normal.

**BREED**

Shih Tzu

**Left atrium:** The left atrium is normal.

**Mitral valve:** The mitral valve is diffusely thickened with minimal prolapse into the left atrial lumen. Mild mitral regurgitation with a normal velocity.

**SEX**

Male Neutered

**Aortic valve/aorta:** The aortic valve is normal in morphology and mobility. Normal aortic outflow velocity; laminar flow. No aortic insufficiency.

**Right ventricle:** Normal right ventricular diameter and morphology indicating no overt evidence of pulmonary arterial hypertension.

**AGE**

7 years

**Right atrium:** Normal RA dimension.

**Tricuspid valve:** The tricuspid valve appears normal with trivial tricuspid regurgitation.

**Pulmonic valve/pulmonary artery:** The pulmonic valve is normal in morphology and mobility. No pulmonic insufficiency. Normal RVOT velocity; laminar flow.

**Pericardium/other:** No pericardial or pleural effusion noted. No obvious cardiac masses.

**Heart rhythm:** ECG reveals a sinus rhythm with an average HR of 150bpm.

**WEIGHT**

17.9lbs

**2-Dimensional Measurements**

**Doppler Measurements**

Ao diam (cm)	1.5
LA diam (cm)	1.7
LA:Ao (Swe)	1.1
IVS thickness (cm)	0.7
LVID diastole (cm)	2.4
PW thickness (cm)	0.7
LVID systole (cm)	1.2
FS (%)	49

PV Vmax (m/s)	0.7
AoV Vmax (m/s)	1.1
MR Vmax (m/s)	4.8
TR Vmax (m/s)	NA
TR PG (mmHg)	NA

**INTERPRETED BY**

Maggie Machen  
Lamy, DVM  
DACVIM (Cardiology)

**INTERPRETATION OF THE FINDINGS**

The cause of the murmur is chronic degenerative valve disease causing mild mitral and trivial tricuspid regurgitation. Lack of significant left atrial enlargement indicates the current risk for complication is low. No concurrent issues such as systolic dysfunction or pulmonary hypertension are noted in this study. Assessment of progression in the future will help predict long term prognosis, which is highly variable at this stage (B1).

**IMAGING PERFORMED BY**

Pamela Harrigan,  
RDMS

**HOSPITAL NAME**

East Boston Animal  
Hospital

**REFERRING VET**

Dr. Chopra

Given these findings, the cough is unlikely to be cardiac in origin and primary respiratory causes should be considered. Consider further respiratory work up/treatment (hydrocodone, taper course of steroids, Enrofloxacin, TTW/BAL, etc.).

**INVOICE**

26425

**RECOMMENDATIONS**

- In a dog without significant left atrial enlargement, no cardiac medications are clearly indicated.
- Omega fatty acid supplementation and mild salt restriction may be of some long-term benefit.

**DATE**

9/18/22



**PATIENT**

Bobby Alves

**SPECIES**

Canine

**BREED**

Shih Tzu

**SEX**

Male Neutered

**AGE**

7 years

**WEIGHT**

17.9lbs

**INTERPRETED BY**

Maggie Machen  
 Lamy, DVM  
 DACVIM (Cardiology)

**IMAGING PERFORMED BY**

Pamela Harrigan,  
 RDCS

**HOSPITAL NAME**

East Boston Animal  
 Hospital

**REFERRING VET**

Dr. Chopra

**INVOICE**

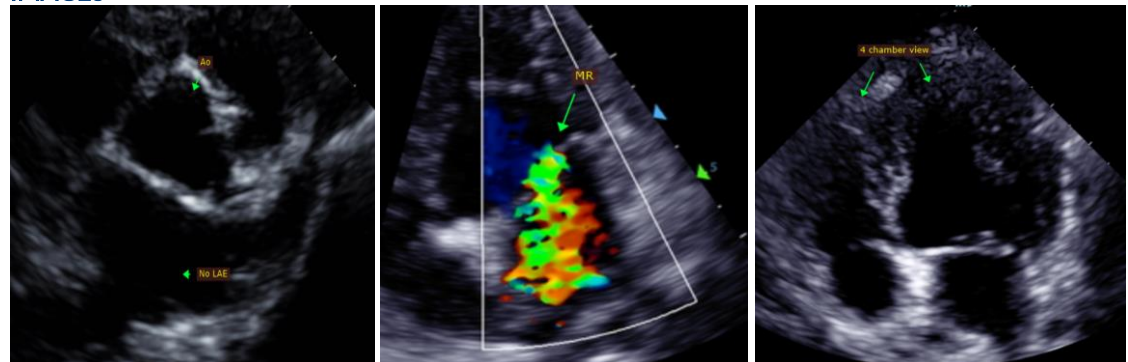
26425

**DATE**

9/18/22

- Anesthetic risk is considered mild if needed. Cardiac protective drug choices (opioid/benzodiazepine premedication, propofol or alfaxalone induction, isoflurane gas) are recommended. Pre-oxygenate for 5-10 minutes prior to induction. Monitor for arrhythmias, hypotension, and hypoxia both intra and post-operatively and intervene as necessary. Mild IV fluid restriction is recommended to avoid fluid overload. Avoid heart rate stimulating drugs such as atropine unless clinically indicated.
  - Monitor for development of a cough, labored breathing, exercise intolerance or collapse episodes.
- PLAN**
- Recommend conservative monitoring with a recheck echocardiogram in 6 months, sooner if any development of clinical signs.

**IMAGES**



The information and recommendations provided are based on the images presented by the referring veterinarian. No evaluation can be communicated regarding pathology that was not visible in the image/video clips provided.

Thank you for this referral. This report was generated using transcription software, and minor dictation errors may be present. If the clinical or image interpretation does not parallel your findings or if I can be of any further assistance, please contact me.

Maggie Machen Lamy, DVM  
 Diplomate of the American College of Veterinary Internal Medicine (Cardiology)  
 info@sonopath.com